Received: 10 December 2019 | Accepted: 29 April 2020

DOI: 10.1111/epi.16549

Check for updates

FULL-LENGTH ORIGINAL RESEARCH

Epilepsia®

pCREB expression in human tissues from epilepsy surgery

Dalia De Santis[1] | **Laura Rossini**[1] | **Laura Tassi**[2] | **Giuseppe Didato**[1] | **Giovanni Tringali**[3] | **Massimo Cossu**[2] | **Manuela Bramerio**[4] | **Francesco Padelli**[5] | **Maria Cristina Regondi**[1] | **Francesca Colciaghi**[1] | **Eleonora Aronica**[6,7] | **Roberto Spreafico**[1] | **Rita Garbelli**[1]

[1]Epilepsy Unit, Fondazione IRCCS Istituto Neurologico Carlo Besta, Milan, Italy

[2]Claudio Munari Epilepsy Surgery Center, Niguarda Hospital, Milan, Italy

[3]Neurosurgery Unit, Fondazione IRCCS Istituto Neurologico Carlo Besta, Milan, Italy

[4]Department of Pathology, Niguarda Hospital, Milan, Italy

[5]Scientific Department, Fondazione IRCCS Istituto Neurologico Carlo Besta, Milan, Italy

[6]Department of (Neuro) Pathology, University of Amsterdam, Amsterdam UMC, Amsterdam, The Netherlands

[7]Stichting Epilepsie Instellingen Nederland (SEIN), Zwolle, The Netherlands

Correspondence
Rita Garbelli, Epilepsy Unit, Fondazione IRCCS Istituto Neurologico *C. Besta*, Via Amadeo 42, 20133 Milano, Italy.
Email: rita.garbelli@istituto-besta.it

Funding information
AICE-FIRE, Grant/Award Number: RA101; Italian Ministry of Health, Grant/Award Number: RF-2016-02362195

Abstract

Objective: Activity-dependent changes have been reported in animal models and in human epileptic specimens and could potentially be used as tissue biomarkers to evaluate the propensity of a tissue to generate seizure activity. In this context, cAMP-response element binding protein (CREB) activation was specifically reported in human epileptic foci and related mainly to interictal spike activity. To get further insights into CREB activation in human epilepsy, we analyzed pCREB expression on brain tissue samples from patients who underwent surgery for drug-resistant focal epilepsy, correlating this expression with intracranial stereo–electroencephalography (SEEG) recording in a subgroup.

Methods: Neocortical specimens from patients with neuropathological diagnosis of no lesion (cryptogenic), malformations of cortical development,mainly type II focal cortical dysplasia (FCD), and hippocampi with and without hippocampal sclerosis have been analyzed by immunohistochemistry. Peritumoral cortex from non-epileptic patients and autoptic samples were used as controls, whereas rat brains were used to test possible loss of pCREB antigenicity due to fixation procedures and postmortem delay.

Results: pCREB was consistently expressed in layer II neuronal nuclei in regions with normal cortical lamination both in epileptic and non-epileptic surgical tissues. In patients with SEEG recordings, this anatomical pattern was unrelated to the presence of interictal spike activity. Conversely, in the core of type II FCD, as well as in other developmental malformations, pCREB was scattered without any laminar specificity. Furthermore, quantitative data did not reveal significant differences between epileptic and non-epileptic tissues, except for an increased immunoreactivity in the core of type IIB FCD lesion related mainly to reactive glial and balloon cells.

Significance: The present data argue against the reliability of pCREB immunohistochemistry as a marker of epileptic focus but underscores its layer-related expression, suggesting a potential application in the study of malformations of cortical development, a wide range of diseases arising from perturbations of normal brain development.

© 2020 International League Against Epilepsy

KEYWORDS
epilepsy surgery, human tissue, pCREB expression, SEEG recording

1 | INTRODUCTION

Epilepsy is a brain disease characterized by abnormal neuronal activity causing seizures. In epilepsy surgery, the presence of a focal epileptogenic lesion is a good predictor of post-operative seizure outcome, and the histopathological nature of the lesion plays an important role. It is also known that "normal-appearing tissue" adjacent to a lesion (perilesion) or tissue with no specific lesion at histology and imaging (cryptogenic) may contribute to generating seizures. In both cases, it would be interesting to have a diagnostic marker to evaluate the propensity of a tissue to generate seizure activity for the prognosis, but also to better understand the pathomechanisms of epileptogenicity. An ideal diagnostic tissue marker should provide information about the extent of the epileptogenic area in order to determine whether resection is complete.

Because ictal and interictal spikes produce activity-dependent changes, several attempts have been made to identify potential tissue biomarkers for epilepsy, and genes encoding receptors, ion channels, transcription factors, or heat shock proteins may be candidates.[1–4] In this context, the activation of cAMP-response element binding protein (CREB) was specifically reported in human epileptic foci and mainly related to interictal spike activity.[5–7]

CREB belongs to the bZIP superfamily of transcription factors, which bind to cAMP-response-element (CRE) promoter sites on target genes. In neurons, a wide range of extracellular stimuli are capable to activate CREB, by phosphorylation at Ser133, resulting in regulation of numerous cellular functions such as responses to growth factors during the development of the nervous system, depolarization and synaptic activity during normal neuronal function, as well as in hypoxia and stress responses during stroke or neural injury. CREB is highly expressed in both neurons and glia and its transactivation potential is regulated in an activity-dependent manner. Thus, robust neuronal activity has been shown to trigger the phosphorylation of CREB at serine 133, an event necessary for CREB-dependent transcription.[8–10]

Although several data have been collected in animal models of epilepsy,[11–16] to our knowledge only few papers have been devoted so far to study pCREB expression in human tissues, particularly in human post-surgical epileptic tissues.[5–7,17,18] For instance, Rakhade *et al*[5] using a phosphoserine-133–specific antibody in neocortical epileptic tissues with several underlying pathology, found marked pCREB expression in most neuronal nuclei in layers II and III at the epileptic focus but not in the adjacent not spiking "control" tissue, whereas the small astrocytic nuclei were not labeled with this antibody. The same group, later, with transcriptome analysis strongly implicated MAPK-CREB signaling and CREB-dependent transcription in human epileptic neocortex removed after invasive electrocorticography. They found that 84% of neurons were pCREB-positive in layer II/III in the epileptic focus compared with 5% in adjacent "control" regions.[7] These data, together with the evidence that induction of interictal spiking in rat neocortex was able to produce a specific pattern of CREB phosphorylation in layer II/III neurons,[19] suggested the potential use of pCREB as a tissue marker of epileptic area.

Key Points

- pCREB is consistently expressed in layer II neuronal nuclei in epileptic and non-epileptic tissues in regions with normal cortical lamination
- In malformations of cortical development, pCREB is dispersed without any laminar specificity
- Glial cells and balloon cells strongly express pCREB immunoreactivity
- Quantitative data do not reveal significant differences among groups except for an increased immunoreactivity in the core of type IIB Focal Cortical Dysplasia (FCD) lesion

To get further insights into CREB activation in human epilepsy and to verify the reliability of pCREB expression as a possible marker of epileptic focus, we performed a set of experiments on post-surgical tissues derived from patients admitted to surgery for drug-resistant focal epilepsy and with different neuropathological diagnosis. Human autoptic tissues and control rat brains were also used for comparison.

2 | METHODS

2.1 | Subjects and neuropathology

The study includes the analysis of brain tissue specimens from 32 patients who underwent epilepsy surgery for drug-resistant epilepsy at "*Carlo Besta*" Neurological Institute Foundation and "*Claudio Munari*" Epilepsy Surgery Center at the Niguarda Hospital (Milan, Italy). The ethics committees of both institutes approved the diagnostic and therapeutic procedures and the use of surgical specimens for research. Presurgical, surgical, and neuropathological procedures at the two institutes are identical, according to

the published guideline approved by the Lombardy Region Welfare Directorate (Decreto no 1865, 15.03.2016). In 11 of 32 patients invasive stereo-electroencephalography (SEEG) was performed before surgery and in 6 patients the SEEG electrodes were used to produce focal lesions by means of radiofrequency thermocoagulation (RF-THC) at the end of the recordings.[20,21] A total of 27 surgical neocortical specimens were examined: 7 from cryptogenic patients, in whom imaging and neuropathological investigation have not revealed detectable structural lesion; 10 patients with diagnosis of type IIb focal cortical dysplasia (FCD), and 6 with type IIa, both characterized by disrupted cortical lamination and the presence of giant cells (dysmorphic neurons only, IIa; and dysmorphic neurons with balloon cells, IIb), hallmarks of this dysplasia. Then, we further add two samples from patients affected by hemimegaloencephaly (HME) and two samples from patients with tuberous sclerosis complex (TSC), sharing histological alterations similar to type II FCD. Six hippocampi with (n = 4) and without (n = 2) hippocampal sclerosis were also analyzed. Resections were performed for strictly therapeutic reasons after the patients had given informed consent. The extent of the excision was planned pre-operatively to minimize the risks of postsurgical deficits based on the epileptogenic zone (EZ) location and imaging data. Seizure outcome was assessed according to Engel classification at least 2 years after surgery, unless otherwise indicated. For comparison, three peritumoral cortices from non-epileptic patients and five control autoptic samples were also considered. Autopsies were performed within 24-48 hours after death intervened for non-neurological causes (see Table 1).

2.2 | Human tissue preparation and immunostaining

After surgery, resected brain specimens were immediately immersed in 4% paraformaldehyde (PFA) buffered solution for 24-36 hours, subsequently cut in 5 mm-thick slabs, and paraffin embedded. Serial 7 μm-thick sections were stained with hematoxylin and eosin, thionin, Luxol Fast Blue (LFB), or processed for immunohistochemistry with the following primary monoclonal antibodies: against neuronal nuclei (NeuN; Chemicon, Temecula, CA, diluted 1:1000) to evaluate cortical lamination and neuronal density; neuronal non-phosphorylated neurofilaments (SMI311R; Covance, San Diego, CA, 1:250) as a marker of dysmorphic neurons; glial-fibrillary acidic protein (GFAP; Chemicon, 1:1000) for astrogliosis; intermediate filament protein vimentin (Dako, Carpinteria, CA, USA, 1:1000) as a marker for balloon cells; and phospho-CREB (pCREB Ser133; Cell Signaling Technology, Danvers, MA, US, 1:800). Single-label immunohistochemistry was developed using an avidin-biotin peroxidase method and 3,3-diaminobenzidine (Sigma, St Louis, MO) as chromogen, as described elsewhere.[22] Sections were counterstained with hematoxylin. The specificity for the primary antibodies was tested by western blotting (WB) analysis in our material (pCREB) or proven by manufacturer's technical information. To test for the specificity of secondary antibodies, sections were submitted to the same experimental protocol, except for the omission of the primary antibodies. No immunostaining was ever observed under these conditions.

For double-labeling, representative sections in selected cases were incubated in a mixture of pCREB (1:800) and NeuN (1:1000) or Calbindin D-28K (Swant Bellinzona, Switzerland, 1:1000) to identify neurons and layer II/III interneurons, respectively, in cryptogenic patients, and SMI311R (1:300), or MAP2 (NeoMarkers, Fremont, CA, 1:100) or vimentin (1:300) in type II FCD cases. Then a mixture of Alexa Fluor 488 donkey anti-rabbit (Immunological Sciences, 1:500) and Alexa 555 Fluor donkey anti-mouse (1:400) was used. For Calbindin, a Streptavidin Cy2 (Jackson Immunoresearch, 1:600) amplification protocol was used. Sections were then analyzed using a Nikon D-Eclipse C1 laser scanning confocal microscope (Nikon).

2.3 | Quantitative evaluation and statistic

To quantitatively evaluate the expression pattern of pCREB in selected cases, one representative section per case, chosen in the middle of the resection, was used. We considered two regions of interest (ROIs) covering the full thickness of the gray matter and one in the white matter chosen in the areas of the most intense immunostaining and, in cases explored with SEEG, far from the electrode tracks. In type II FCD cases, we further considered two different histopathologically defined areas: (a) the core of the lesion (L), with the maximal cytoarchitectural alterations; (b) and an adjacent transition area, called perilesion (P), presenting only minimal alterations. The ROIs varied according to the regions (L, P) and cases with a mean value of 2.5 ± 1.3 mm^2. The expression of pCREB was evaluated using an image analysis system (Image-Pro Premier 9.1 software; Media Cybernetics). Density of pCREB-positive cells was estimated using densitometric analysis that combined user-defined color intensity threshold and size and shape parameters of the objects of interest. The size parameter was used to differentiate the cellular components: glial nuclei (with a diameter ranging between 3-5 micron), vs neuronal nuclei (9-12 micron) vs giant nuclei (14-20 micron, belonging to dysmorphic neurons, balloon cells); these ranges were based on preliminary estimate of nuclear diameters of the different components on thionin-stained sections (20 nuclei for each class in two cryptogenic and two type IIB FCD cases with nucleolus clearly

TABLE 1 Main clinical data of the patients

ID	Site	Age at autopsy (y)	ID	SITE	Age at surgery (y)
No EPI-autopsy			*No EPI-surgery (peritumoral)*		
1	T	79	6[a]	F	na
2	T	64	7	T	70
3	T	67	8[a]	F	71
4	T, O	60			
5	T, O	32			

ID	Site	Age at surgery (y)	Age at seizure onset (y)	Duration of epilepsy (y)	Monthly seizure frequency	SEEG	RF-THC	Outcome (Engel class)
EPI-crypto								
1[a]	T	24	18	6	10	No	No	IB
2[a]	T	43	39	4	3	Yes (Coregistered)	Yes	IA
3[a]	T	30	16	14	4	Yes (Coregistered)	Yes	IA
4[a]	F	26	8	18	2	Yes	Yes	IV
5	F	44	19	25	12	Yes (Coregistered)	No	IA
6[b]	T	38	27	11	8	No	No	II (≤2 y)
7[b]	T	33	26	7	20	No	No	IA (≤2 y)
EPI -FCDIIb								
8[a]	T	25	0	25	50	No	No	IA
9	T	12	2	10	100	Yes	No	IA
10	T	40	6	34	1	Yes (Coregistered)	Yes	IA
11[a]	F	31	17	14	9	Yes (Coregistered)	No	IA
12	F	4	1	3	100	No	No	IA
13[a]	F	31	4	27	90	No	No	IA
14[a]	F	26	13	13	90	No	No	IA
15[a]	P	46	6	40	75	No	No	IA
16[a]	F	34	1	33	16	No	No	IA
17	F	29	11	18	60	No	No	na (≤1 y)
EPI-FCDIIa								
18[a]	T	37	13	24	6	Yes	Yes	IA
19	F	40	6	34	2	yes	Yes	IA
20[a]	TO	2	0	2	150	No	No	IA
21	O	14	1	13	100	No	No	IA
22[a]	O	6	0	6	200	Yes	No	IA
23[a]	F	9	1	8	600	Yes	No	IA
EPI-HME								
24	FT	0	0	0	na	No	No	na
25	FTP	0	0	0	30	No	No	IV
EPI-TS								
26	F	44	0	44	8	No	No	IC
27	F	43	15	28	10	No	No	na (≤1 y)
EPI-noHS								
1	T	24	18	6	10	No	No	IB

(Continues)

TABLE 1 (Continued)

ID	Site	Age at surgery (y)	Age at seizure onset (y)	Duration of epilepsy (y)	Monthly seizure frequency	SEEG	RF-THC	Outcome (Engel class)
2	T	39	17	22	6	No	No	IA
EPI-HS								
3	T	36	3	33	6	No	No	IB
4	T	24	3	21	24	No	No	IA
5	T	53	19	34	3	No	No	IA
6	T	36	14	22	4	No	No	IA

Abbreviations: F, frontal; FCD, focal cortical dysplasia; ID, identification number; na, not available; O, occipital; RF-THC, radiofrequency thermocoagulation; SEEG, stereo-electroencephalography; T, temporal; y, years.

[a]Cases for immunoreactivity quantification.

[b]Cases for western blotting.

visible). Statistical analysis was performed with Origin version 8.0 software. Averaged data were expressed as mean ± standard deviation (SD) and the differences in cell density among groups were assessed using one-way analysis of variance (ANOVA) followed by Tukey's post hoc test. Correlation tests were performed between the density of pCREB-positive cells and the following clinical parameters: age at seizure onset, monthly seizure frequency, and epilepsy duration.

2.4 | Western blotting

Snap frozen cortical surgical samples from two epileptic patients and two autopsy controls were processed, as reported previoulsy,[23] for WB analysis of pCREB. Briefly, 100-150 mg of cortical tissue was homogenized in ice-cold lysis buffer (sucrose 0.32 mol/L, Hepes 10 mmol/L pH 7.4, PMSF 0.1 mmol/L, $MgCl_2$ 1 mmol/L, $NaHCO_3$ 1 mmol/L) in the presence of a complete set of protease inhibitors (CompleteTM, Roche) by 10 strokes of a motor-driven glass-Teflon potter. Total crude homogenates were separated by SDS-PAGE (8%) and were electroblotted onto nitrocellulose and incubated with specific monoclonal antibody raised against pCREB (dilution 1:500, Cell Signaling) in Odyssey Blocking Buffer (LI-COR Biosciences) and PBS (1:1) overnight at 4°C. A monoclonal pan actin antibody was used as loading control (dilution 1:4000, #MAB1501R, Millipore). Primary antibodies were detected with IRDye (680 or 800 nm) labeled goat-anti-rabbit or goat-anti-mouse IgG (LI-COR Biosciences) incubated for 1 hour at RT at 1:10,000 dilution. Immunoreactive bands were visualized by means of Odyssey Infrared Imaging System (LI-COR Biosciences). Intensity scan parameters for 700 or 800 nm channels were optimized for each target protein to prevent saturation of signals and were kept constant for each sample analyzed.

2.5 | Animals

To evaluate possible immunohistochemical alterations due to the modality and delay of fixation, a set of experiments with animals were performed. Three female Sprague-Dawley adult rats (Charles River Italia) were deeply anesthetized with 10 mg/kg Zoletil and 10 mg/kg Xylazin. One rat was transcardially perfused with 4% PFA in 0.1 mol/L phosphate buffer (PB), pH 7.2, by means of a peristaltic pump; the brain was removed from the skull and post-fixed in 4% PFA for 24 hours. To mimic the operational procedures for epilepsy surgery, the brain of the second rat (not perfused) was extracted from the skull and immediately fixed by immersion in 4% PFA buffered solution for 36 hours. To mimic autoptic tissue, the brain of the third rat was removed from the skull after 24 hours from the sacrifice and cut in two hemispheres: One hemisphere was immediately immersed in 4% PFA for 24 hours, the other immersed in artificial cerebrospinal fluid for 24 hours and subsequently in 4% PFA for 24 hours. Brains and hemispheres from all rats were embedded in paraffin and cut into serial 7 μm-thick sections by means of a microtome. Selected sections for each specimen were processed for immunohistochemistry with primary antibody against pCREB (1:800) as described previously.

All the experiments were performed in accordance with the guidelines defined by the European Communities Council Directive (2010/63/EU) and the experimental protocol was approved by the Internal Ethics Committee of Neurological Institute "Carlo Besta" (DO-01-2016).

3 | RESULTS

To analyze pCREB expression in human brain samples, we used a commercial antibody produced with a synthetic phosphopeptide corresponding to residues surrounding Ser133 of human CREB. WB analysis of whole cortical homogenates

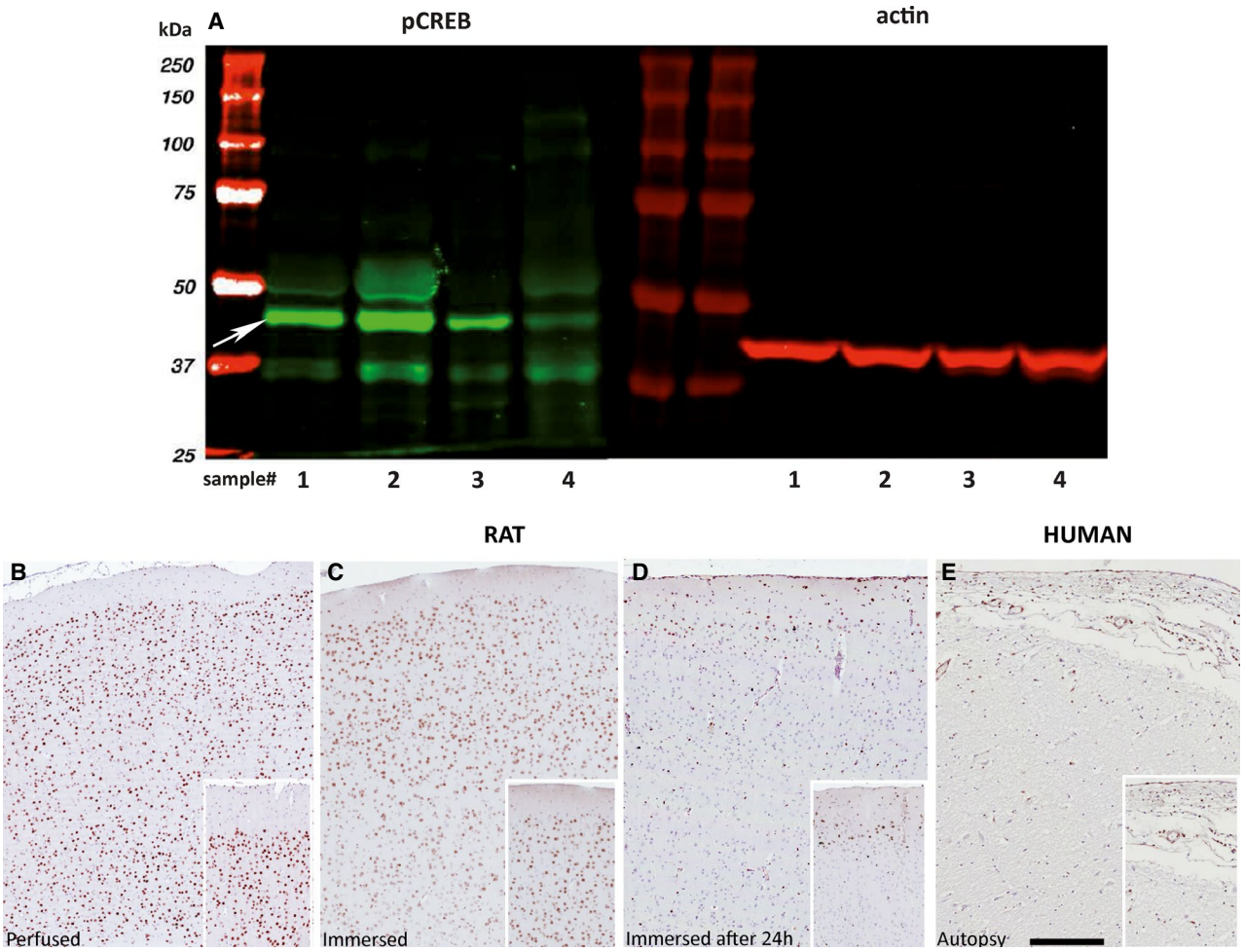

FIGURE 1 A, Total homogenates of surgical (samples 1, 2) and autoptic (samples 3, 4) human cerebral cortices were analyzed by western blotting using the pCREB (Ser133) antibody (left panel, green). pCREB antibody detects a principal band migrating at about 45 kDa (arrow) and a minor band at around 37 kDa, in agreement with manufacturer's technical information, less intense in autoptic tissues. On the right (red immunoreactive bands), actin immunostaining as loading control. B-D,Examples of pCREB immunoreactivity (ir) in rat sections showing the different expression due to different fixation procedures. Section from perfused animal (B) shows an intense pCREB ir in neuronal nuclei in all cortical layers, while sections from brain fixed by immersion immediately (C) and after 24 h from the sacrifice (D) highlight the dramatic reduction of ir and the appearance of labeled meningeal and glial cells. A pattern similar to those observed in D is present in human autopsy (E), suggesting the unreliability of this tissue as control. Scale bars: 190 μm (B-E)

performed in two representative surgical specimens and two representative autoptic specimens revealed that the antibody recognized a principal band migrating at 45 kDa and a minor band at about 37 kDa, in agreement with manufacturer's technical information, in both surgical and, at lower level, autoptic human cortices (Figure 1A, left panel, green immunoreactive bands). Immunoblot analysis of actin, as loading control, performed in the same samples (Figure 1A right panel, red immunoreactive bands) did not reveal evident difference between surgical and autoptic samples.

Because our interest was to investigate pCREB activation in human epileptic tissue in comparison to available non-epileptic control, we performed a set of experiments to test possible impairment of pCREB antigenicity due to fixation procedures and postmortem delay to validate the use of autoptic control. To this purpose, we used control rat brain and different fixation procedures: transcardiac perfusion-fixation, considered as the gold standard procedure for the retention of the antigenicity, and immersion-fixation performed either immediately after the sacrifice or 24-48 hours after the sacrifice to mimic autoptic tissue.

In the perfused animal, pCREB was abundantly expressed in cortical neurons with a nuclear subcellular localization (Figure 1B) and in all layers without any evident expression in glial cells. In the rat brain with immersion-fixation, we observed depth-related variations in staining intensity with a maximal intensity in the superficial vs deep layers (Figure 1C). Small nuclei of presumptive glial cells were visible in the white matter. Moreover, in brain hemispheres fixed by immersion with a postmortem delay of 24-48 hours, pCREB immunoreactivity was scarce. In fact, scattered labeled neurons were limited to the superficial layers, whereas

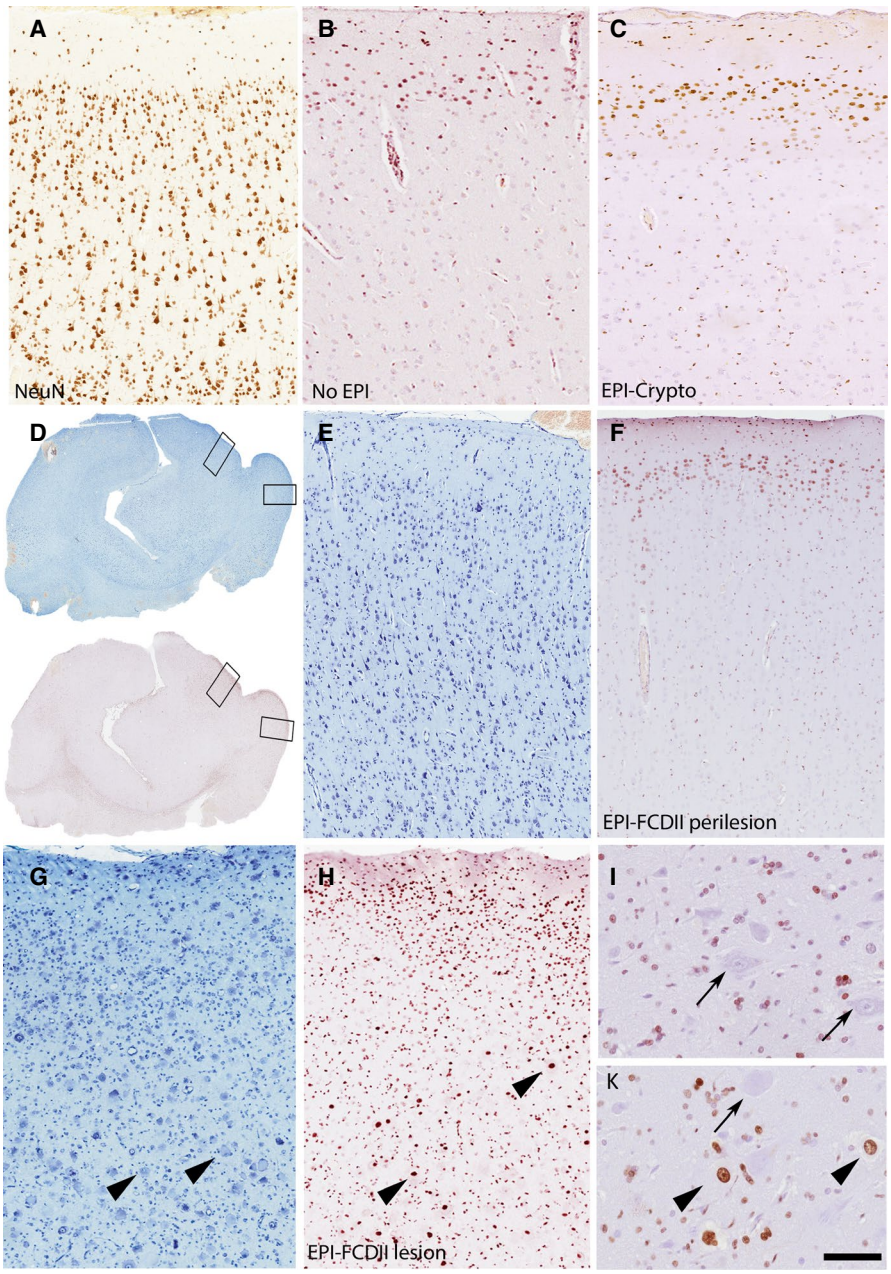

FIGURE 2 Examples of pCREB ir in different human cortices. In non-epileptic peritumoral cortex, the ir is mainly confined in layer II neuronal nuclei (B), as confirmed in adjacent NeuN-stained section (A), and in diffuse glial nuclei. A similar pattern is present in cryptogenic samples (C). In type II FCD, different patterns may be present in the same section (E): in perilesional area (F, thionin) the ir is present in layer II neuronal nuclei (G), whereas in the core of the lesion (H, thionin) the ir is diffuse in all cortical thickness in nuclei of different size (I). Dysmorphic neurons are clearly negative in both type IIa and IIb FCD (J, K, arrows), whereas balloon cells are strongly positive (I,K, arrowheads). Scale bars: 120 μm (A-C); 50 μm (D-F)

meningeal and glial cells were the most consistent findings (Figure 1D). In human autoptic tissues, we observed a pattern similar to that found in rat with postmortem delay with positive nuclei of meningeal cells, rare and scattered small nuclei, and some endothelial cells (Figure 1E). Overall, these data suggested that human autoptic tissues were not suitable controls to compare pCREB expression differences between nonepileptic and epileptic tissues; therefore, we used noninfiltrated peritumoral cortices from patients operated on for brain tumor as proper controls.

In peritumoral cases, we obtained a consistent staining in layer II neuronal nuclei, as assessed by NeuN-stained adjacent section (Figure 2A), and a diffuse immunoreactivity in small nuclei in both gray and white matter, with a great variability between individual cases (Figure 2B).

We then analyzed the expression pattern of pCREB in neocortical tissues considered part of the EZ based on electroclinical criteria. In both cryptogenic samples (Figure 2C) and perilesional area of type IIa and IIb FCD cases, we found findings similar to those observed in peritumoral tissues (Figure 2G). In FCD cases we observed a clear-cut difference moving, within the same section (Figure 2D,E), from the perilesional area (Figure 2F), toward the core of the lesion (Figure 2H), where pCREB immunoreactivity was dispersed throughout the entire cortex in nuclei of different sizes (Figure 2I). Dysmorphic neurons were negative in both type IIa/IIb FCD (Figure 2J,K), whereas balloon cells, only present in type IIb FCD, were strongly positive (Figure 2I,K). Double immunofluorescent labeling showed that in cryptogenic cases the majority of superficial pCREB-labeled nuclei

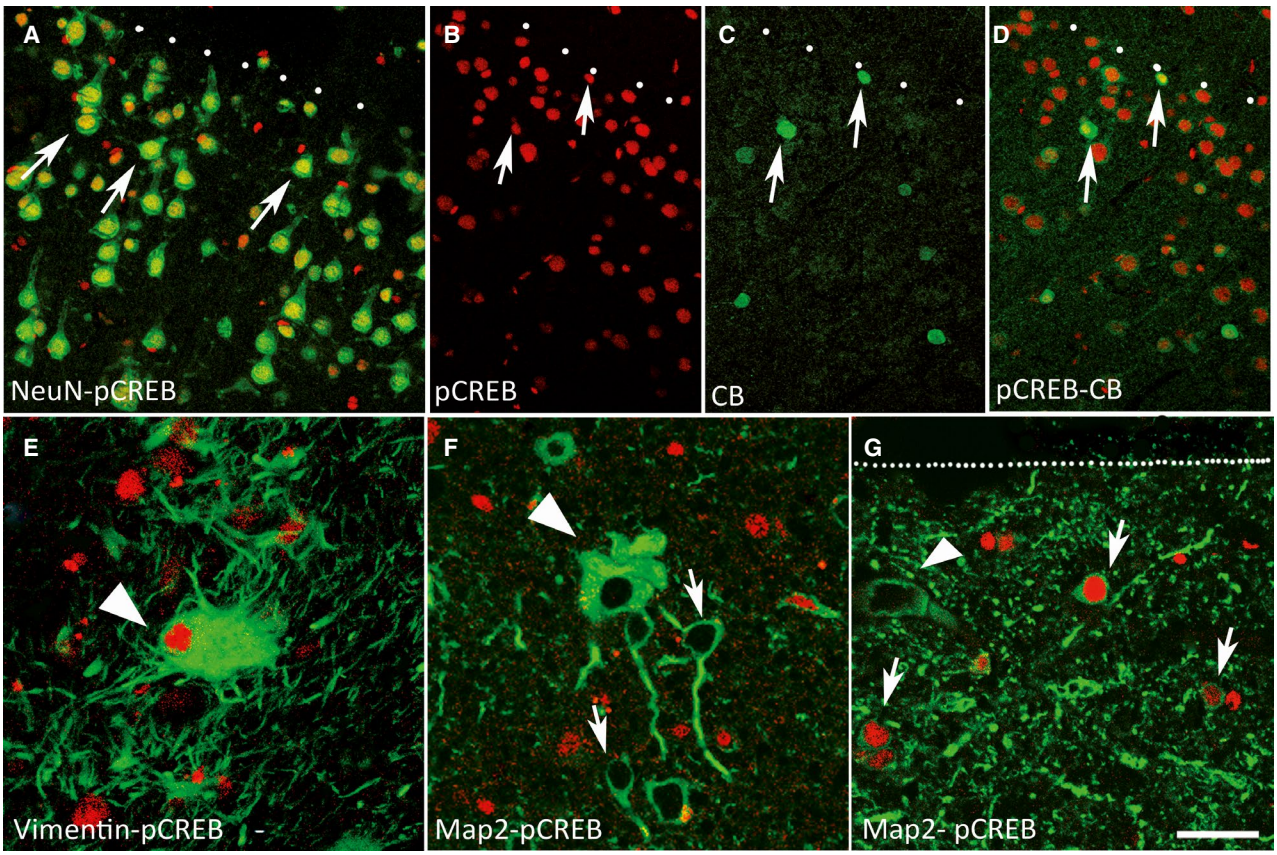

FIGURE 3 Double labeling immunofluorescent staining for pCREB (red) and neuronal markers (NeuN or CB, green) in a cryptogenic case showing that pCREB ir is localized in all NeuN-positive superficial neurons (A, arrows) and in scattered layer II CB-positive interneurons (B-D, arrows). In type IIb FCD, vimentin-positive balloon cells are pCREB-positive (E), whereas MAP2-positive dysmorphic neurons are negative (F,G, arrowheads). Normal-looking neurons are pCREB-negative (F, arrows) in the deep layers but positive in layer II (G, arrows). White dots indicate layer I-II border. Scale bars: 65 μm (A-D); 30 μm (E-G)

colocalized with NeuN-positive neurons (Figure 3A) but rarely with CB-positive interneurons (Figure 3B-D). In the core of type IIb FCD, we confirmed the presence of pCREB in balloon cells (Figure 3E) but not in dysmorphic neurons (Figure 3F,G); superficial normal-looking neurons retain their pCREB immunoreactivity (Figure 3G).

Invasive SEEG recording performed before surgery in 11 patients clearly demonstrated that the analyzed tissues were part of the EZ. In five of them (three cryptogenic and two FCD IIb, Table 1), using a coregistration protocol,[24] we were able to reconstruct the anatomical localization of the SEEG implanted electrodes with the identification of the single leads on the histological slices. In this way, we correlated the intracranial EEG pattern with the pCREB immunoreactivity with high accuracy. In sections from these specimens, all involved in seizure generation, we observed a persistent layer II immunoreactivity in the regions with normal cortical lamination regardless of the presence/absence of interictal spikes (Figure 4).

The pCREB expression in cerebral cortices was quantified in a subgroup. We did not find significant mean density differences among the different epileptic tissues and peritumoral control tissues. However, a trend for higher density was observed in type IIb FCD lesion both in gray and white matter (Figure 5A,B). Considering the gray matter only (Figure 5C-E), the majority of the counted-positive objects were glial nuclei (3-5 micron) in all groups. Giant nuclei (14-20 micron) were observed only in type IIb FCD and corresponding to balloon cells, as demonstrated with double immunofluorescence experiments, whereas the intermediate size (9-12 micron), including normal neurons and presumably reactive astrocytes, were significantly higher in the lesional regions of type IIb FCD ($P = .036$). There was no correlation between pCREB expression and seizure frequency, duration of epilepsy, and age at onset in the histological subgroups both in gray and white matter (data not shown).

This strong expression in glial cells was further confirmed in the hippocampal sclerosis, where immunohistochemical pCREB analysis revealed an increased expression in comparison to nonsclerotic hippocampi (compare Figure S1A vs S1B) and the immunoreactivity was almost exclusively in nuclei of reactive astrocytes (Figure S1C-H).

We then asked whether the presence of a pCREB dispersion throughout the cortex observed in the core of the type

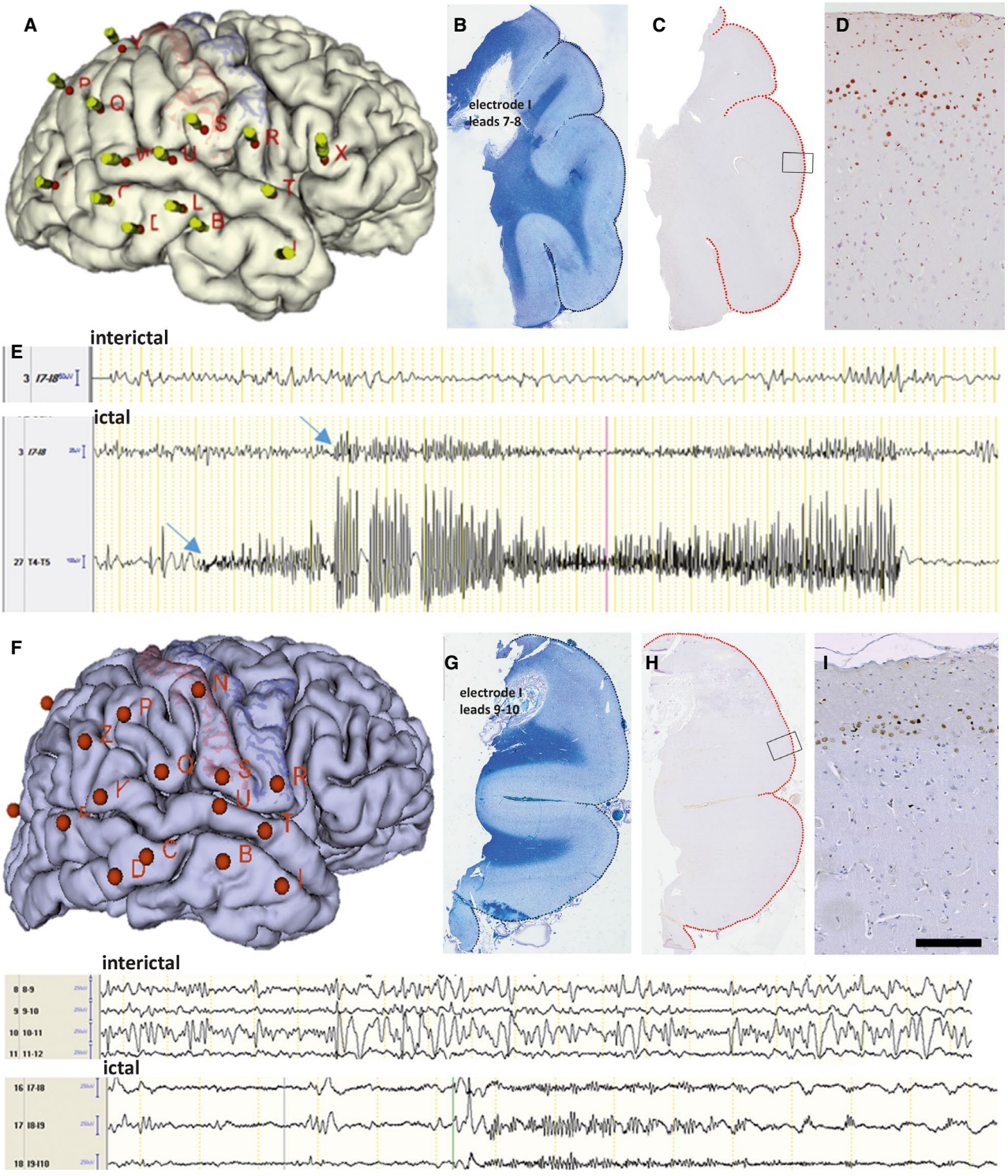

FIGURE 4 Correlations between SEEG recordings and pCREB expression in two cryptogenic patients. A,F: 3D Slicer reconstructions showing the electrodes entry points. LFB- (B,G) and adjacent pCREB-stained sections (C,D,H,I) where leads of the electrode I are recognized. Note in both patients, the typical pCREB staining in layers II neuronal nuclei (D,I). E,J: Examples of interictal and ictal activity from the electrodes and leads identified on the histology. The electrode I in the first patient shows the absence of interictal abnormalities (E, upper row) and its secondary involvement in ictal activity first originating from electrode T (E, lower rows). In the second patient, the electrode I shows interictal spikes and slow waves activity (J, upper rows) and a seizure recorded from the same electrode (J, lower rows). Scale bars: 3 mm (B-C-G-H); 190 μm (D-I)

II FCD was a common feature in samples presenting cortical dyslamination and giant/dysmorphic cells. For this reason, we analyzed specimens from patients with HME and cortical tubers from patients with TSC (Figure S2). In both cases, we observed a diffuse pCREB immunoreactivity in regions with cortical alterations (Figure S2A-D), confirming

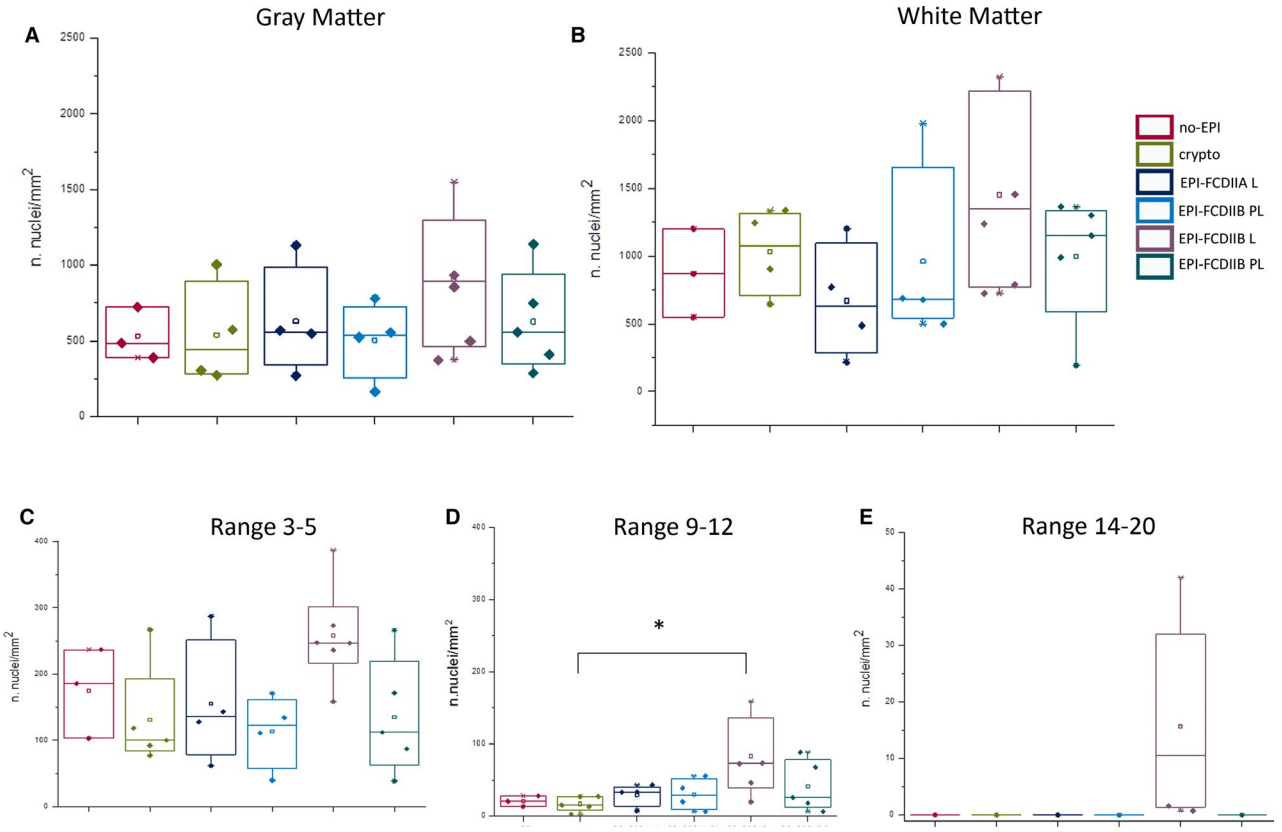

FIGURE 5 Box plots, representing the quantification of the total pCREB ir, do not shown significant differences among groups in gray (A) and white matter (B). Segregating the counted-positive cells in gray matter with respect to the different nuclear size, the plots underline the high level of expression in glial nuclei in all groups (C), the significant increase in intermediate size nuclei (including normal-neurons and probably reactive astrocytes, D) and the presence of giant nuclei (balloon cells) in the lesional region of type IIb FCD (E). Statistical significance is indicated by asterisk (*$P < .05$)

that the majority of the immunoreactivity was linked to glial and balloon cells (Figure S2F,G,H,I,J) but not to dysmorphic neurons (Figure S2E,H). Superficial normal-looking neurons, when present, retained their pCREB immunoreactivity (Figure S2B) as noted in FCD.

4 | DISCUSSION

Activity-dependent changes have been reported in animal models of epilepsy and in human epileptic specimens and thus are potentially used as tissue biomarkers to evaluate the propensity of a tissue to generate seizure activity. In this context, CREB activation was specifically reported in human epileptic foci.[5–7] To validate and to expand this observation in cases with high epileptogenic lesions such as type II FCD, this paper analyzed pCREB expression in postsurgical epileptic tissues with different neuropathological diagnosis, correlating the anatomical pattern with the ictal and interictal electrical activity recorded with intracranial electrodes in a subgroup of patients.

Comparison with brain control tissues was mandatory. Because CREB activation is triggered by a variety of internal and external stimuli, a comparison between epileptic and non-epileptic areas within the same patient's brain could be ideal and not biased by differences in genetic background, tissue processing, or antiepileptic medications. However, such tissue is not available as a rule, since only cortical areas part of the EZ are removed from surgery. Two different types of controls were considered: autoptic tissues and surgical peritumoral tissues from non-epileptic patients. Autopsy control tissue is ideal, but it is essential to know the antigen decay due to postmortem autolysis; on the contrary resected histologically normal tissue adjacent to a nonepileptic pathology (ie, tumor) had an ideal fixation, comparable with epilepsy surgery specimens, with no significant hypoxia damage. To explore this possible scenario, we tested several autoptic, peritumoral tissues, and used rat brains in different experimental condition as reference for pCREB immunoreactivity.

In general, experiments on animal models required transcardial perfusion, allowing the best results for immunohistochemical procedures; conversely, neuropathological research on human tissue is performed using a fixation procedure by immersion. For these reasons, we wanted to test differences in pCREB expression in different fixation modalities and timing. As clearly demonstrated in the presented results, striking differences have been observed among perfused rat brains

and those fixed by immersion, which showed not only a reduction of the intensity of staining but also the appearance of stained glial cells, rarely present in the perfused specimen. Moreover, a progressive decrease of staining with residual labeled cells only in the superficial cortical layers and few scattered glial cells was observed when fixation (by immersion) was delayed at 24 and 48 hours after animal sacrifice.

Our results from the perfused animal are similar to those presented by others[25,26] who used a similar procedure but different from those reported by Barkmeier et al[19] in non-spiking (control) hemisphere, although technical details are not reported in this last paper. Others, using immersion-fixation, found pCREB expression in the upper neocortical layers.[27] Altogether, these results on animal models show that pCREB expression, as revealed by immunohistochemistry, is very sensitive to tissue handling.

Human autoptic tissues, at either 24 or 48 hours after death and in any evaluated cortical region, did not show neuronal or glial staining, with only moderate immunoreactivity at the meningeal and endothelial elements. This lack of immunostaining in brain autopsy was reported by others,[28] and in the majority of the papers on Alzheimer's disease, where CREB signaling dysfunction was investigated for its role in memory formation, only WB technique has been used to study this protein, further confirming difficulty in antigen preservation.[29] Moreover, also using WB technique it has been demonstrated that postmortem interval rapidly decreased the levels of proteins in their phosphorylated states including pCREB expression.[30] For these reasons, normal tissue adjacent to tumor remains the only available non-epileptic control, even if neoplastic cells may have aberrant CREB expression.[28,31,32]

Aware of these limitations, the main findings of this study are that: (a) pCREB is consistently expressed in layer II neuronal nuclei in both epileptic and non-epileptic tissues in regions with normal cortical lamination; (b) in the core of type II FCD, as well as in other developmental malformations, pCREB is dispersed throughout all the cortex mainly confined in glial and balloon cells; and (c) quantitative measurements do not reveal significant differences between epileptic and non-epileptic tissues.

The pCREB expression in layer II/III neurons was previously observed in human cortex only in cortical regions identified as "epileptic" by means of electrocorticography and suggested as a typical and restricted pattern useful as epileptic biomarker.[5,7] Our qualitative results showing a similar pattern in cryptogenic tissues, in which intracerebral recording clearly documented interictal and ictal epileptic activity and in non-epileptic controls did not confirm these data. To reinforce this discrepancy, we observed a diffuse pCREB expression in malformed/dysplastic tissues known to be intrinsically epileptogenic and here proved with intracerebral recordings in a subgroup of our patients. Moreover, quantitative data of pCREB immunoreactivity highlight the absence of significant differences among cryptogenic, dysplastic, and nonepileptic tissues. Although we have no explanation for these discrepancies with previous data, the present report suggests the unreliability of pCREB as a tissue marker of epileptic foci. Unfortunately, we did not have the opportunity to validate these data using other quantitative approaches, such as WB technique, due to the insufficient availability of fresh tissues representative of the different neuropathological diagnosis.

One interesting aspect that emerges from these data is the consistent expression of pCREB immunoreactivity in superficial layer neurons in non-malformed tissues, irrespective of the examined cortical region. This layer-related expression could have potential applications in the study of malformations of cortical development such as type II FCD, HME, and TSC characterized, by contrast, by a widespread pCREB expression throughout the cortex without any laminar specificity. In all these cases, the majority of the immunoreactivity was linked to glial and balloon cell nuclei, except residual layer II/III normal-looking neurons, when present, in agreement with the hypothesis that only abnormal cells have an altered migratory pattern.[33] Thus, this peculiar pCREB expression would have a merely morphological and not the functional significance for the identification of epileptogenic foci.

Dysmorphic neurons considered hyperexcitable cells and suggested to play an important role in the generation of epileptic activity, did not display pCREB immunoreactivity, whereas balloon cells and reactive astrocytes, considered electrically inert, exhibited strong nuclear expression.[34] This intense expression in glial cells and particularly in reactive astrocytes was not unexpected and previously reported. In fact, Park et al[17] found chronic activation of CREB in the nucleus of reactive astrocytes in the sclerotic hippocampus, but not in the residual neurons in pyramidal layer and dentate gyrus. Moreover, activation of the ERK/MAPK pathway, a cascade of kinases that once triggered lead to CREB phosphorylation, was already documented in reactive glia of human epileptic hippocampus and animal epileptic tissue.[35,36] Because reactive astrocytes exhibit many unusual properties compared to astrocytes from nonepileptic brain, such as changes in membrane proteins, membrane physiology, gene expression, and neurovascular relationship, a role for ERK/MAPK signaling in astrogliosis may be suggested.[37]

ACKNOWLEDGMENTS

This study was supported by the Italian Ministry of Health grant RF-2016-02362195 to RG plus AICE-FIRE RA101 to LR. The authors thank Dr B. Cipelletti for her technical support.

CONFLICT OF INTEREST

None of the authors has any conflict of interest to disclose. We confirm that we have read the Journal's position on the

issues involved in ethical publication, and affirm that this report is consistent with those guidelines.

ORCID

Dalia De Santis https://orcid.org/0000-0002-2519-2067
Massimo Cossu https://orcid.org/0000-0002-1891-7648
Rita Garbelli https://orcid.org/0000-0002-6475-4974

REFERENCES

1. Baybis M, Yu J, Lee A, Golden JA, Weiner H, McKhann G, et al. mTOR cascade activation distinguishes tubers from focal cortical dysplasia. Ann Neurol. 2004;56(4):478–87.
2. Becker AJ, Chen J, Zien A, Sochivko D, Normann S, Schramm J, et al. Correlated stage- and subfield-associated hippocampal gene expression patterns in experimental and human temporal lobe epilepsy. Eur J Neurosci. 2003;18(10):2792–802.
3. Najm I, Ying Z, Babb T, Crino PB, Macdonald R, Mathern GW, et al. Mechanisms of epileptogenicity in cortical dysplasias. Neurology. 2004;62(6 Suppl 3):S9–S13.
4. Sarnat HB, Flores-Sarnat L. α-B-crystallin as a tissue marker of epileptic foci in paediatric resections. Can J Neurol Sci. 2009;36(5):566–74.
5. Rakhade SN, Yao B, Ahmed S, Asano E, Beaumont TL, Shah AK, et al. A common pattern of persistent gene activation in human neocortical epileptic foci. Ann Neurol. 2005;58(5):736–47.
6. Rakhade SN, Shah AK, Agarwal R, Yao B, Asano E, Loeb JA. Activity-dependent gene expression correlates with interictal spiking in human neocortical epilepsy. Epilepsia. 2007;48(Suppl 5):86–95.
7. Beaumont TL, Yao B, Shah A, Kapatos G, Loeb JA. Layer-specific CREB target gene induction in human neocortical epilepsy. J Neurosci. 2012;32(41):14389–401.
8. Lonze BE, Ginty DD. Function and regulation of CREB family transcription factors in the nervous system. Neuron. 2002;35(4):605–23.
9. Herdegen T, Fiallos-Estrada C, Schmid W, Bravo R, Zimmermann M. The transcription factor CREB, but not immediate-early gene encoded proteins, is expressed in activated microglia of lumbar spinal cord following sciatic nerve transection in the rat. Neurosci Lett. 1992;142(1):57–61.
10. West AE, Griffith EC, Greenberg ME. Regulation of transcription factors by neuronal activity. Nat Rev Neurosci. 2002;3(12):921–31.
11. Moore AN, Neal Waxham M, Dash PK. Neuronal activity increases the phosphorylation of the transcription factor cAMP response element-binding protein (CREB) in rat hippocampus and cortex. J Biol Chem. 1996;271(24):14214–20.
12. Lee B, Dziema H, Lee KH, Choi Y-S, Obrietan K. Obrietan K. CRE-mediated transcription and COX-2 expression in the pilocarpine model of status epilepticus. Neurobiol Dis. 2007;25(1):80–91.
13. Ong WY, Lim HM, Lim TM, Lutz B. Kainate-induced neuronal injury leads to persistent phosphorylation of cAMP response element-binding protein in glial and endothelial cells in the hippocampus. Exp Brain Res. 2000;131(2):178–86.
14. De Armentia ML, Jancic D, Olivares R, Alarcon JM, Kandel ER, Barco A. cAMP response element-binding protein-mediated gene expression increases the intrinsic excitability of CA1 pyramidal neurons. J Neurosci. 2007;27(50):13909–18.
15. Porter BE, Lund IV, Varodayan FP, Wallace RW, Blendy JA. The role of transcription factors cyclic-AMP responsive element modulator (CREM) and inducible cyclic-AMP early repressor (ICER) in epileptogenesis. Neuroscience. 2008;152(3):829–36.
16. Zhu X, Han X, Blendy JA, Porter BE. Decreased CREB levels suppress epilepsy. Neurobiol Dis. 2012;45(1):253–63.
17. Park SA, Kim TS, Choi KS, Park HJ, Heo K, Lee BI. Chronic activation of CREB and p90RSK in human epileptic hippocampus. Exp Mol Med. 2003;35(5):365–70.
18. Guo J, Wang H, Wang Q, Chen Y, Chen S. Expression of p-CREB and activity-dependent miR-132 in temporal lobe epilepsy. Int J Clin Exp Med. 2014;7(5):1297–306.
19. Barkmeier DT, Senador D, Leclercq K, Pai D, Hua J, Boutros NN, et al. Electrical, molecular and behavioral effects of interictal spiking in the rat. Neurobiol Dis. 2012;47(1):92–101.
20. Cossu M, Cardinale F, Castana L, Citterio A, Francione S, Tassi L, et al. Stereoelectroencephalography in the presurgical evaluation of focal epilepsy: a retrospective analysis of 215 procedures. Neurosurgery. 2005;2005:57(4).
21. Cossu M, Fuschillo D, Casaceli G, Pelliccia V, Castana L, Mai R, et al. Stereoelectroencephalography-guided radiofrequency thermocoagulation in the epileptogenic zone: a retrospective study on 89 cases. J Neurosurg. 2015;123(6):1358–67.
22. Garbelli R, Munari C, De Biasi S, Vitellaro-Zuccarello L, Galli C, Bramerio M, et al. Taylor's cortical dysplasia: a confocal and ultrastructural immunohistochemical study. Brain Pathol. 1999;9(3):445–61.
23. Colciaghi F, Nobili P, Cipelletti B, Cagnoli C, Zambon S, Locatelli D, et al. Targeting PSD95-nNOS interaction by Tat-N-dimer peptide during status epilepticus is neuroprotective in MAM-pilocarpine rat model. Neuropharmacology. 2019;153:82–97.
24. Zucca I, Milesi G, Padelli F, Rossini L, Gozzo F, Figini M, et al. An image registration protocol to integrate electrophysiology, MRI and neuropathology data in epileptic patients explored with intracerebral electrodes. J Neurosci Methods. 2018;303:159–68.
25. Pennacchio P, Noé F, Gnatkovsky V, Moroni RF, Zucca I, Regondi MC, et al. Increased pCREB expression and the spontaneous epileptiform activity in a BCNU-treated rat model of cortical dysplasia. Epilepsia. 2015;56(9):1343–54.
26. Chen B, Wang JF, Hill BC, Young LT. Lithium and valproate differentially regulate brain regional expression of phosphorylated CREB and c-Fos. Mol Brain Res. 1999;70(1):45–53.
27. Rybnikova E, Gluschenko T, Tulkova E, Churilova A, Jaroshevich O, Baranova K, et al. Preconditioning induces prolonged expression of transcription factors pCREB and NF-κB in the neocortex of rats before and following severe hypobaric hypoxia. J Neurochem. 2008;106(3):1450–8.
28. Barresi V, Mondello S, Branca G, Rajan TS, Vitarelli E, Tuccari G. P-CREB expression in human gliomas: Potential use in the differential diagnosis between astrocytoma and oligodendroglioma. Hum Pathol. 2015;46(2):231–8.
29. Bartolotti N, Bennett DA, Lazarov O. Reduced pCREB in Alzheimer's disease prefrontal cortex is reflected in peripheral blood mononuclear cells. Mol Psychiatry. 2016;21(9):1158–66.
30. Li J, Gould TD, Yuan P, Manji HK, Chen G. Post-mortem interval effects on the phosphorylation of signaling proteins. Neuropsychopharmacology. 2003;28(6):1017–25.
31. Daniel P, Filiz G, Brown DV, Hollande F, Gonzales M, D'Abaco G, et al. Selective CREB-dependent cyclin expression mediated by

the PI3K and MAPK pathways supports glioma cell proliferation. Oncogenesis. 2014;3(6):e108.
32. Barresi V, Branca G, Caffo M, Tuccari G. p-CREB expression in human meningiomas: correlation with angiogenesis and recurrence risk. J Neurooncol. 2015;122(1):87–95.
33. Rossini L, Medici V, Tassi L, Cardinale F, Tringali G, Bramerio M, et al. Layer-specific gene expression in epileptogenic type II focal cortical dysplasia: Normal-looking neurons reveal the presence of a hidden laminar organization. Acta Neuropathol Commun. 2014;2(1).1–15.
34. Cepeda C, Hurst RS, Flores-Hernández J, Hernández-Echeagaray E, Klapstein GJ, Boylan MK, et al. Morphological and electrophysiological characterization of abnormal cell types in pediatric cortical dysplasia. J Neurosci Res. 2003;72(4):472–86.
35. Mandell JW, Vandenberg SR. ERK/MAP kinase is chronically activated in human reactive astrocytes. NeuroReport. 1999;10(17):3567–72.
36. Li YQ, Xue T, Xu J, Xu ZC, Liu H, Chen YM. ERK1/2 activation in reactive astrocytes of mice with pilocarpine-induced status epilepticus. Neurol Res. 2009;31(10):1108–14.
37. de Lanerolle NC, Lee TS, Spencer DD. Histopathology of human epilepsy. In: Noebels JL, Avoli M, Rogawski MA, Olsen RW, Delgado-Escueta AV, eds. Jasper's basic mechanisms of the epilepsies [Internet]. 4th ed. Bethesda, MD: National Center for Biotechnology Information (US); 2012.

SUPPORTING INFORMATION

Additional supporting information may be found online in the Supporting Information section.

How to cite this article: De Santis D, Rossini L, Tassi L, et al. pCREB expression in human tissues from epilepsy surgery. *Epilepsia*. 2020;00:1–13. https://doi.org/10.1111/epi.16549